

# Percutaneous Cement Vertebroplasty & Kyphoplasty: A Minimally Invasive Solution for Osteoporotic Vertebral Fracture

SIM Khairun Nabi Khan<sup>1\*</sup>, Moshiur Rahman<sup>2</sup>, Robert Ahmed Khan<sup>3</sup>, Sk. Farhad Munir<sup>3</sup>, Sujan Sharif<sup>4</sup>

<sup>1\*</sup>Assistant Professor, Neurosurgery Department, BSMMU, Dhaka, Bangladesh.

<sup>2</sup>Assistant Professor, Neurosurgery Department, Holy Family Red Crescent Medical College, Dhaka, Bangladesh.

<sup>3</sup>Medical Officer, Neurosurgery Department, BSMMU, Dhaka, Bangladesh.

<sup>4</sup>Medical Officer (Resident), BSMMU, Dhaka, Bangladesh.

## ABSTRACT

**Introduction:** Osteoporotic fracture is common among the elderly people. It occurs following minor trauma like slipping on the floor or due to jolt while travelling in a vehicle on an uneven road. It is usually associated with severe crippling local pain which aggravates on movement, sitting or standing.

**Objective:** Our goal in this study is to find out the outcome of percutaneous cement vertebroplasty & kyphoplasty for osteoporotic vertebral fracture.

**Methodology:** This cross sectional study was carried out at Department of Neurosurgery, BMSSU, Dhaka from January 2017 to June 2018 where 28 patients data were evaluated on the basis of their history, clinical examination. Among the cases Per. Vertebroplasty was 23 and Balloon kyphoplasty was 5. 60% patients were female and 40% patients were male. The entered data were cross-checked and confirmed.

**Results:** Percutaneous vertebroplasty is a minimally invasive procedure with very good results for the treatment of severe pain due to vertebral compression fracture. It provides significant pain relief with the potential for improving functional outcome.

**Conclusion:** Percutaneous vertebroplasty and balloon kyphoplasty not only relieves pain instantly but can also restore vertebral height.


**Keywords:** Percutaneous Vertebroplasty, Kyphoplasty, Osteoporotic Vertebral Fracture.

## \*Correspondence to:

**Dr. SIM Khairun Nabi Khan,**  
Assistant Professor,  
Neurosurgery Department,  
Bangabandhu Sheikh Mujib Medical University,  
Dhaka, Bangladesh.

## Article History:

Received: 10-12-2018, Revised: 05-01-2019, Accepted: 27-01-2019

Access this article online	
Website: <a href="http://www.ijmrp.com">www.ijmrp.com</a>	Quick Response code 
DOI: 10.21276/ijmrp.2019.5.1.022	

## INTRODUCTION

Osteoporotic fracture is common among the elderly people. It occurs following minor trauma like slipping on the floor or due to jolt while travelling in a vehicle on an uneven road. It is usually associated with severe crippling local pain which aggravates on movement, sitting or standing.

In 1984 Vertebroplasty was developed in France by Galibert and Dera-mond.<sup>1</sup> The unique indication of it was for aggressive vertebral angioma which proven efficacy led to an extension of indications to metastatic and myelomatous osteolytic lesions, and then to osteoporotic vertebral compression fractures. Kyphoplasty was initially developed by Reiley in 1998 from the vertebroplasty concept, then in 2001 taken up by Belkoff et al.<sup>2</sup> After that at first reserved to tumoral and osteoporotic lesions<sup>3</sup>, it has gradually established its role in the treatment of fractures in young patients.<sup>4</sup> The benefit of these minimally invasive techniques compared to conventional attitudes (conservative treatment or open surgery) has been demonstrated in terms of pain and functional

improvement. Cement injection into the vertebra may have an analgesic effect by consolidating microfractures and reducing the mechanical stress associated with weight and activity, and also by destroying bone nerve endings by cytotoxic and exothermal action in the course of cement polymerization. Morbidity, moreover, is minimal and techniques bring cost savings over the medium term.

- Vertebroplasty is a minimally invasive, image-guided therapy used to relieve pain from a vertebral body fracture. Vertebroplasty can increase patient mobility, decrease narcotic needs, and prevent further vertebral collapse.
- Percutaneous vertebroplasty (PVP) usually involves percutaneous injection of cement, polymethylmethacrylate (PMMA), into the vertebral bodies. Occasionally, PMMA has been placed manually into vertebral lesions during open surgical operations.
- Evidence does not support a benefit of kyphoplasty over vertebroplasty with respect to pain, but the procedures may

differ in restoring lost vertebral height, and in safety issues like cement extravasation (leakage).

**Vertebroplasty Procedure: Key Steps and Goals**

- Vertebroplasty is a minimally invasive procedure and patients usually go home the same or next day as the procedure.
- Patients are given local anesthesia and light sedation for the procedure, though it can be performed using only local anesthetic for patients with medical problems who cannot tolerate sedatives well.
- During the procedure, bone cement is injected with a Jamshidi needle into the collapsed or fractured vertebra through pedicle. The needle is placed with fluoroscopic guidance.
- The cement (most commonly PMMA, although more modern cements are used as well) quickly hardens and forms a support structure within the vertebra that provide stabilization and strength.
- Alleviate mechanical back pain
- Prevent further kyphosis
- Enables the performance of a minimally invasive transpedicular biopsy of the vertebral body
- Percutaneous vertebral body augmentation
- Stabilize osteoporotic thoracic and lumbar compression fracture

**Kyphoplasty**

- Kyphoplasty is a variation of a vertebroplasty which attempts to restore the height and angle of kyphosis of a fractured vertebra (of certain types), followed by its stabilization by injected bone cement.
- The procedure typically includes the use of a small balloon that is inflated in the vertebral body to create a void within the cancellous bone prior to cement delivery.
- Once the void is created, the procedure continues in a similar manner as a vertebroplasty, but the bone cement is typically delivered directly into the newly created void.

**Complication**

- Extravasation of cement into the spinal canal
- Breach of pedicle into spinal canal with resultant nerve root or spinal cord injury or intradural/epidural hematoma
- Allergic reaction
- CSF leak
- Infection
- Pulmonary embolus

**Postoperative Course**

- Normally, this can be performed on an outpatient basis
- Depending on medical co-morbidities, the patient may require a 1 or 2 day hospital stay
- Bracing is not necessary
- The patient should be reminded not to do any heavy lifting for several weeks

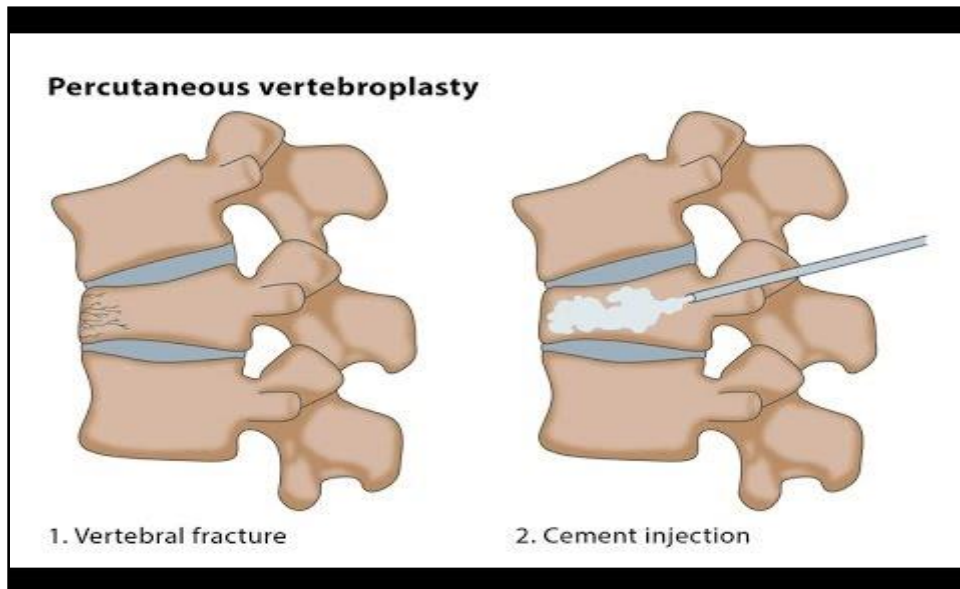


Fig 1a: and 1b: Percutaneous Vertebroplasty

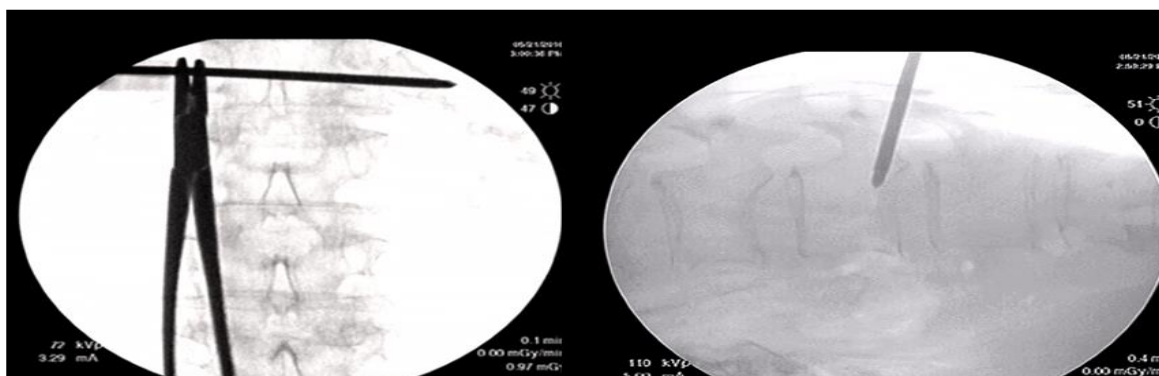


Figure 2: Level identification

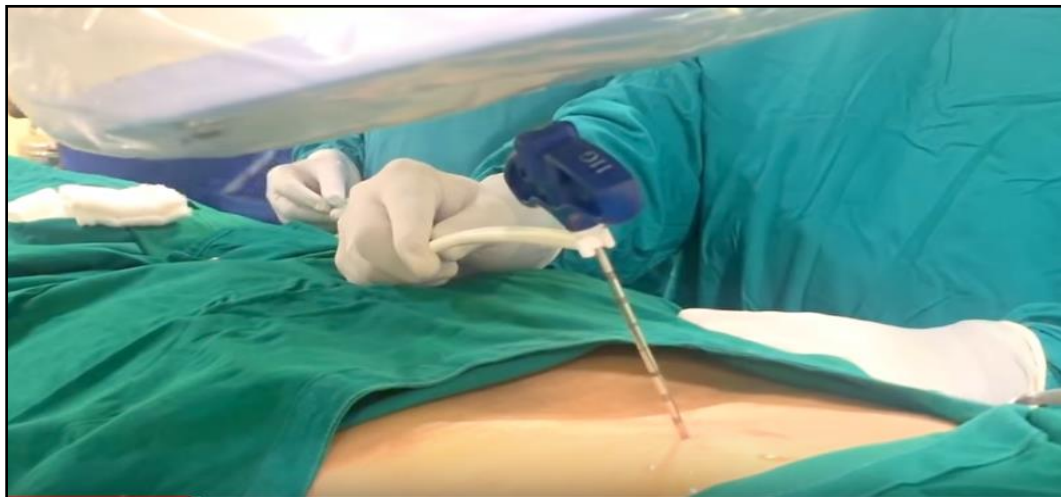

Figure 3: Level identification

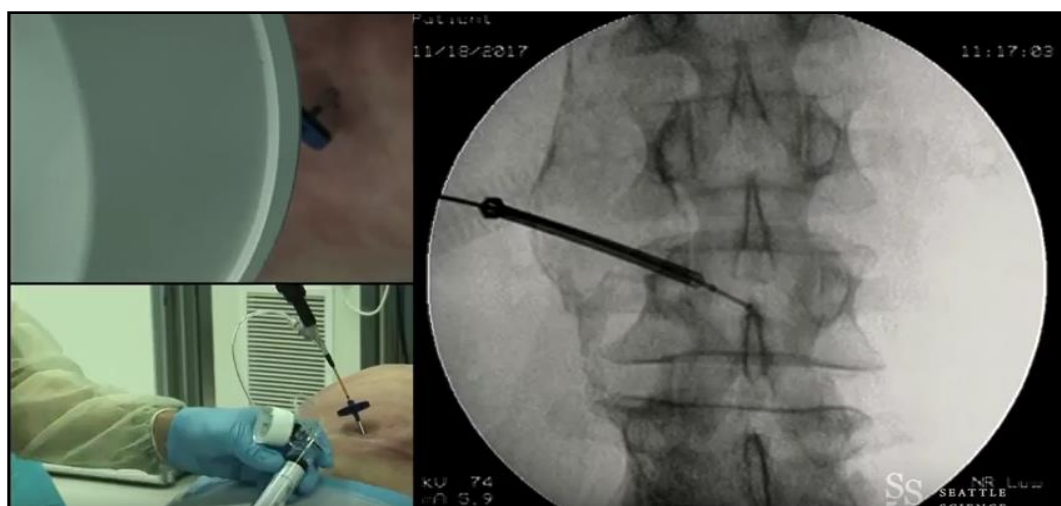

Figure 4: Level identification

## OBJECTIVES

The goal of this study was to find out the outcome of percutaneous cement vertebroplasty & kyphoplasty for osteoporotic vertebral fracture.

## MATERIALS AND METHODS

### Study Type

- This study was a cross sectional analytical study.

### Place and Period of the Study

- This cross sectional study was carried out at Department of Neurosurgery, BMSSU, Dhaka from January 2017 to June 2018.

### Sample Size

- 28 patients were selected by purposive sampling.

### Inclusion Criteria

- Osteoporotic VB compression# (Acute/Chronic)
- Vertebral body tumor- Multiple myeloma
- Patients with intractable, progressive, or non-resolving pain associated an acute or subacute VCF in the thoracic or lumbar spine.

### Data Collection

- A questionnaire was prepared as per protocol and it was filled with the information from of history, clinical examination and investigations by study group.

### Data Management

- On admission, a detailed history of the illness was taken from the patient or attendant, thorough neurological and general examinations were carried out, and findings of the performed investigations were recorded.
- Relevant associated medical conditions were recorded carefully.

### Data Analysis

- Data were presented in tabulated form. The entered data were cross-checked and verified.
- Comparative analysis was done with the help of SPSS and Excel software.

## RESULTS

We have done 28 cases among these

- Per. Vertebroplasty: 23 (82.14%)
- Balloon kyphoplasty: 5 (17.86%)

Among the cases 60% are female and 40% were male patients.

- Percutaneous vertebroplasty is a minimally invasive procedure with very good results for the treatment of severe pain due to vertebral compression fracture.
- It provides significant pain relief with the potential for improving functional outcome.

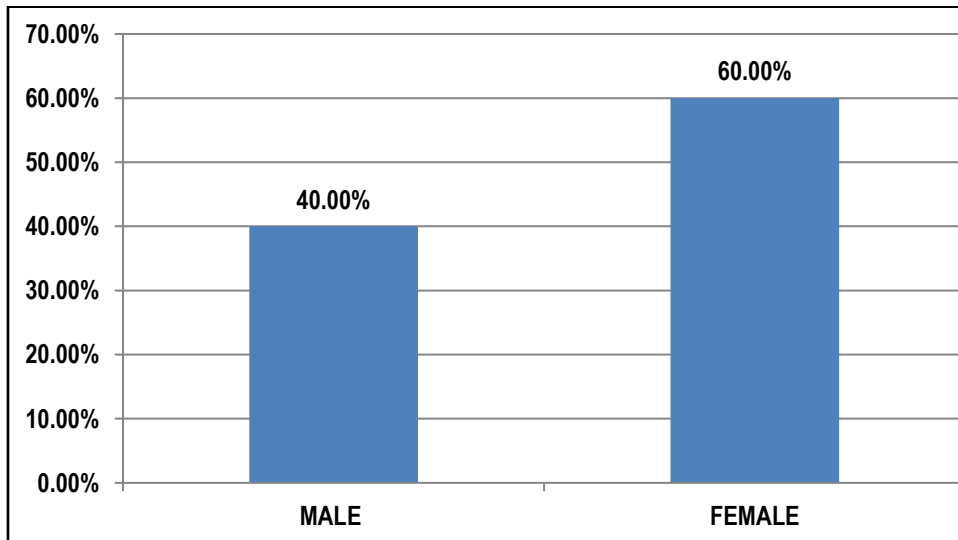


Figure 5: Types of procedure

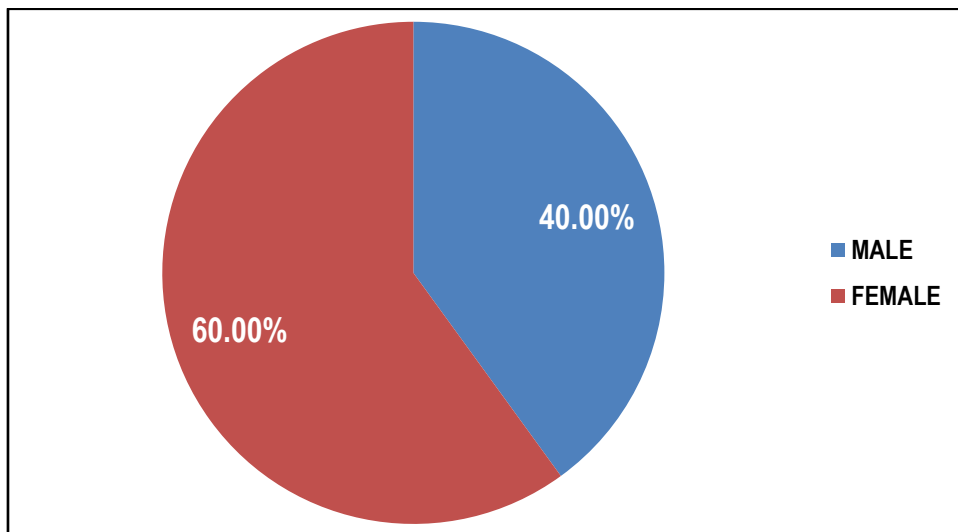


Figure 6: Gender of the patients

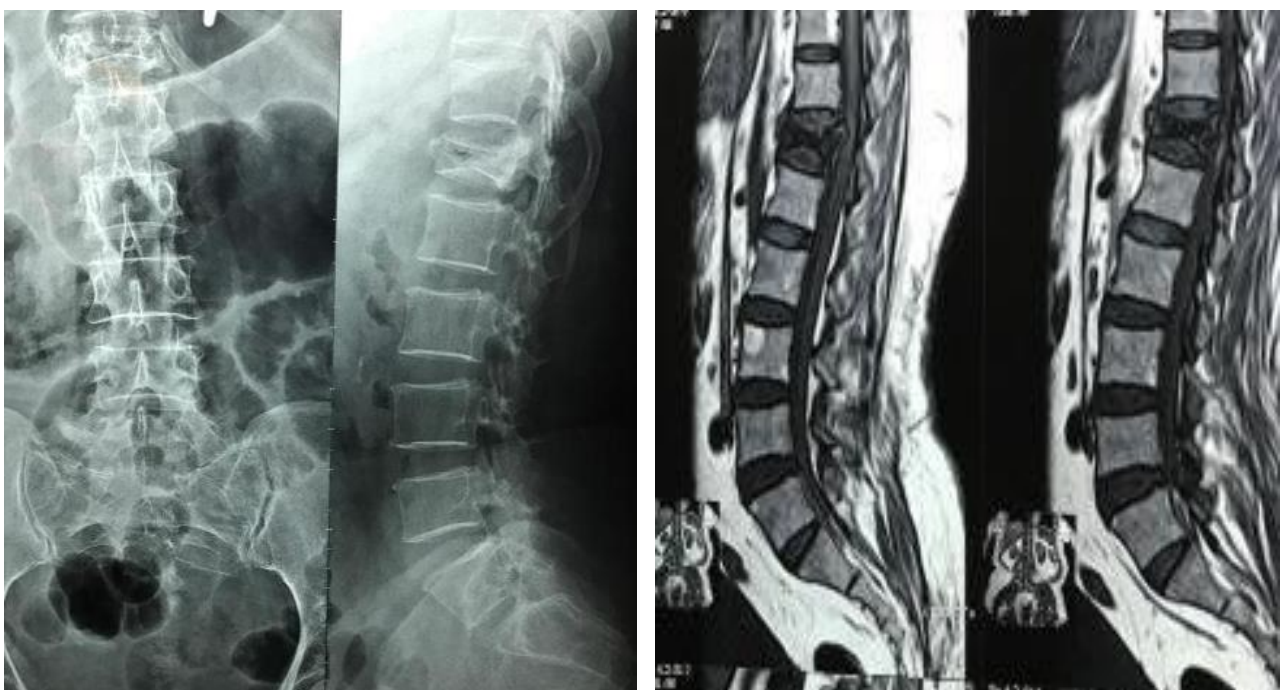
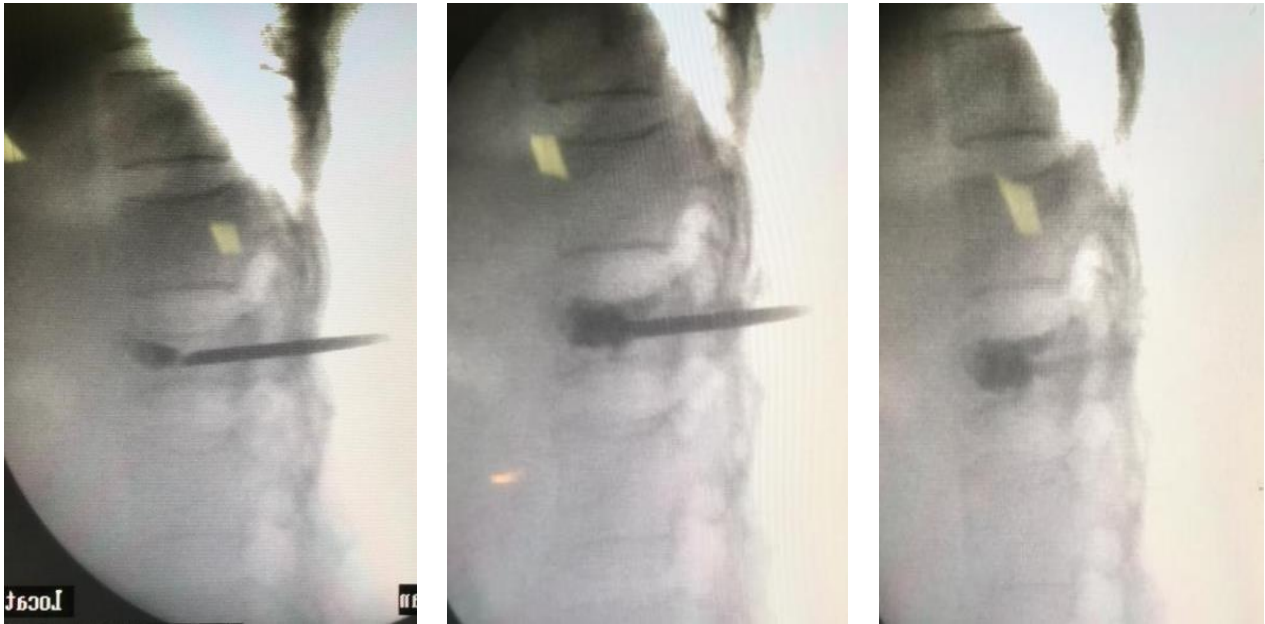
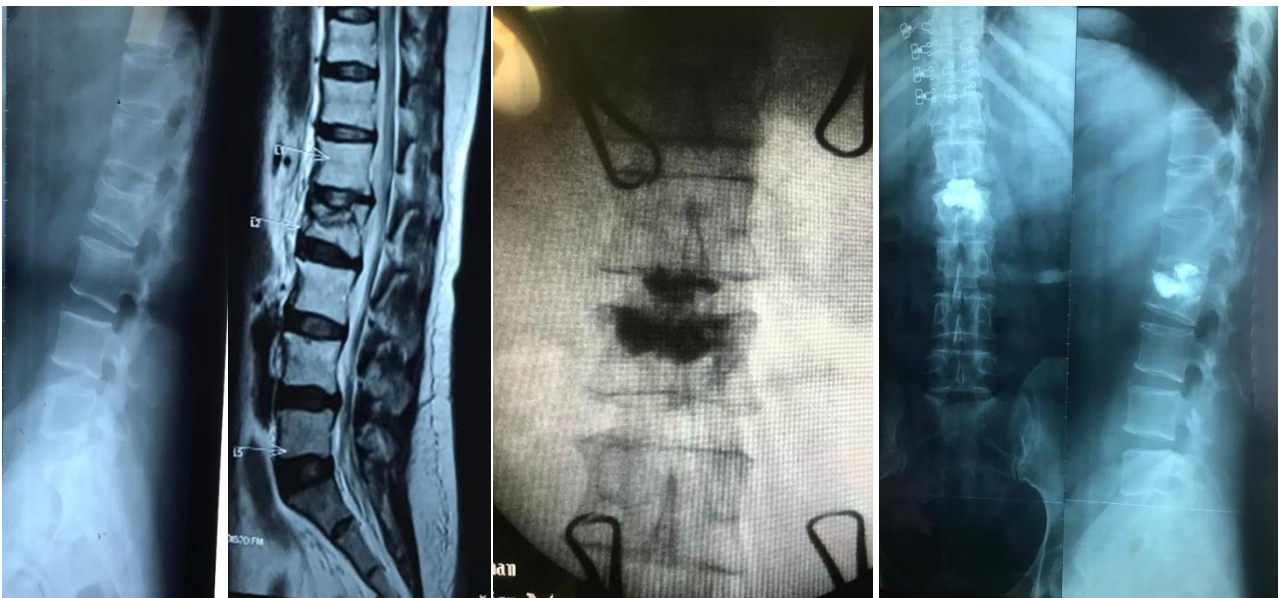
Figure 7: CASE 1: Osteoporotic collapse of D<sub>12</sub> Vertebral body

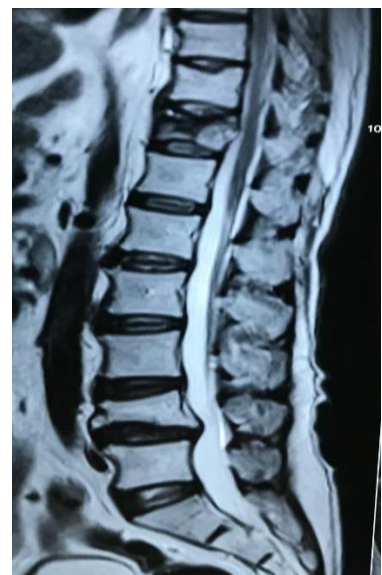
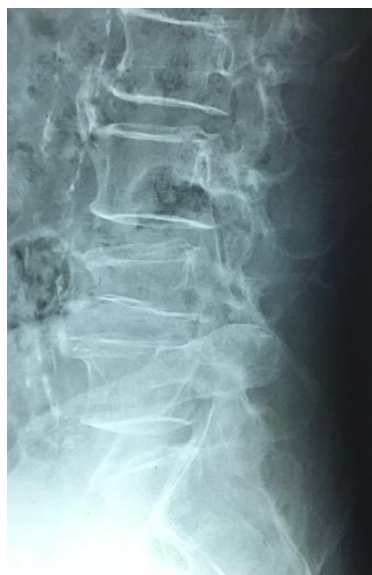
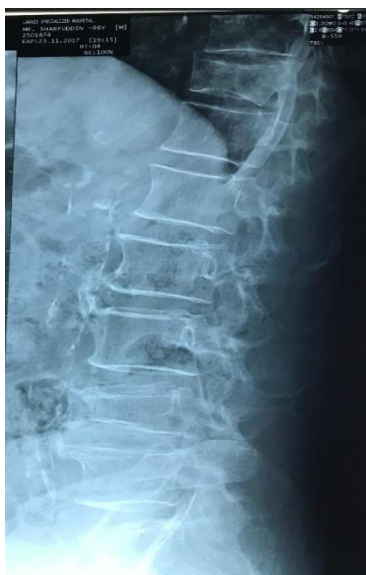**Fig 8:**



**Fig 9: CASE- 2: 49 yr old woman with H/O slip- Immediate X Ray**

**Fig 10: Post-operative x ray MRI of D<sub>12</sub> body collapse which is restored; Sometimes cement may leak**



**Fig 11: Case-3: 67 year old male with H/O fall & severe back pain and unable to stand**

## DISCUSSION

Han et al. in their study identified that vertebroplasty is more effective in the short-term (no more than 7 days) pain relief<sup>5</sup> and Kyphoplasty had a superior capability for intermediate-term (around 3 months) functional improvement. As for long-term pain relief and functional improvement, there was no significant difference between these two interventions. Both interventions were considered to have similar risks with subsequent fracture and cement leakage. Wang et al. concluded that kyphoplasty and vertebroplasty are both safe and effective surgical procedures for the treatment of OVCF.<sup>6</sup> Kyphoplasty has similar long-term pain relief, function outcomes (short-term ODI scores, short- and long-term SF-36 scores), and new adjacent VCFs in comparison to vertebroplasty. Kyphoplasty appears to be superior to vertebroplasty for the injected cement volume, the short-term pain relief, the improvement of short- and long-term kyphotic angle, and lower cement leakage rate. However, kyphoplasty needs longer operation time and higher material cost compared with vertebroplasty. Longo et al. reviewed conservative management of patients with VCFs, and found that no conclusions can be drawn on the superiority of cementoplasty techniques over conservative management.<sup>7</sup> Denaro et al. compared vertebroplasty with kyphoplasty in the treatment of VCFs and reminded us not to forget that for many years successful conservative management of vertebral fractures has been the standard of care.<sup>8</sup> These findings suggest that vertebroplasty and kyphoplasty had no significant difference in VAS scores, ODI scores, OVCF, and radiographic differences. Ma et al. and Wang et al. showed that kyphoplasty has some advantage in decreasing the kyphotic wedge angle, increasing the vertebral body height, and decreasing the risk of cement leakage than vertebroplasty.<sup>9,10</sup>

## CONCLUSION

Percutaneous vertebroplasty and balloon kyphoplasty not only relieves pain instantly but can also restore vertebral height. New technical advances in the development of VP/BKP cements rely on innovative concepts and interdisciplinary knowledge. With the advent of new biodegradable and mechanically matched bone cements, the indications of VP/BKP will likely be broadened, for example, to VCFs with no neurological symptoms in the elderly or even traumatic VCFs in young adults. These types of fractures require bone cements with adjustable mechanical properties that meet the loading requirements early and can be absorbed to avoid stress shielding in the later stage of treatment. If achieved, patients suffering from such fractures may no longer need extra vertebral fixation surgeries. Therefore, a wide spectrum of spinal lesions that were previously left untreated may potentially benefit from these ongoing advancements of bone cements.

## REFERENCES

- Galibert P, Deramond H, Rosat P, Le Gars D. Preliminary note on the treatment of vertebral angioma by percutaneous acrylic vertebroplasty. *Neurochirurgie* 1987;33-2:166-8.
- Belkoff SM, Mathis JM, Fenton DC, Scribner RM, Reiley ME, Talmadge K. An ex vivo biomechanical evaluation of an inflatable bone tamp used in the treatment of compression fracture. *Spine* 2001;26-2:151-6.

- Lieberman IH, Dudeney S, Reinhardt MK, Bell G. Initial outcome and efficacy of "kyphoplasty" in the treatment of painful osteoporotic vertebral compression fractures. *Spine* 2001;26(14):1631-8.
- Maestretti G, Cremer C, Otten P, Jakob RP. Prospective study of standalone balloon kyphoplasty with calcium phosphate cement augmentation in traumatic fractures. *Eur Spine J* 2007;16-5:601-10.
- Han S, Wan S, Ning L, Tong Y, Zhang J, Fan S. Percutaneous vertebroplasty versus balloon kyphoplasty for treatment of osteoporotic vertebral compression fracture: a meta-analysis of randomised and non-randomised controlled trials. *Int Orthop*. 2011;35:1349-58.
- Wang H, Sribastav SS, Ye F, Yang C, Wang J, Liu H, Zheng Z. Comparison of percutaneous vertebroplasty and balloon kyphoplasty for the treatment of single level vertebral compression fractures: a meta-analysis of the literature. *Pain Physician*. 2015;18:209-22.
- Longo UG, Loppini M, Denaro L, Maffulli N, Denaro V. Conservative management of patients with an osteoporotic vertebral fracture: a review of the literature. *J Bone Joint Surg Br*. 2012;94:152-7.
- Denaro V, Longo UG, Maffulli N, Denaro L. Vertebroplasty and kyphoplasty. Clinical cases in mineral and bone metabolism: the official journal of the Italian Society of Osteoporosis, Mineral Metabolism, and Skeletal Diseases. 2009;6:125-30.
- Ma XL, Xing D, Ma JX, Xu WG, Wang J, Chen Y. Balloon kyphoplasty versus percutaneous vertebroplasty in treating osteoporotic vertebral compression fracture: grading the evidence through a systematic review and metaanalysis. *Eur Spine J* : official publication of the European Spine Society, the European Spinal Deformity Society, and the European Section of the Cervical Spine Research Society. 2012;21:1844-59.
- Wang H, Sribastav SS, Ye F, Yang C, Wang J, Liu H, Zheng Z. Comparison of percutaneous vertebroplasty and balloon kyphoplasty for the treatment of single level vertebral compression fractures: a meta-analysis of the literature. *Pain Physician*. 2015;18:209-22.

**Source of Support:** Nil.

**Conflict of Interest:** None Declared.

**Copyright:** © the author(s) and publisher. IJMRP is an official publication of Ibn Sina Academy of Medieval Medicine & Sciences, registered in 2001 under Indian Trusts Act, 1882.

This is an open access article distributed under the terms of the Creative Commons Attribution Non-commercial License, which permits unrestricted non-commercial use, distribution, and reproduction in any medium, provided the original work is properly cited.

**Cite this article as:** SIM Khairun Nabi Khan, Moshir Rahman, Robert Ahmed Khan, Sk. Farhad Munir, Sujan Sharif. Percutaneous Cement Vertebroplasty & Kyphoplasty: A Minimally Invasive Solution for Osteoporotic Vertebral Fracture. *Int J Med Res Prof*. 2019 Jan; 5(1):106-11. DOI:10.21276/ijmrp.2019.5.1.022