

## Acute Pancreatitis Induced by Intra-gastric Balloon

Abdulrahman Mohammed Abu Alqasim, Abdallah Mohammad Alferdaus, Torki Maed Alsalem

General Surgery Department, Aseer Central Hospital, Abha, Saudi Arabia.

### ABSTRACT

Intra-gastric balloon has been shown to result in substantial weight reduction in patients with morbid obesity. However, it has some complications mostly related to the pressure effect and balloon rupture. We present a rare case of pancreatitis induced by insertion of intra-gastric balloon into a 20 years old female. These cases, although rare should be kept in mind when investigating patients with intra-gastric balloons.

**Keywords:** Intra-gastric Balloon, Pancreatitis, Morbid Obesity, Complications.

### INTRODUCTION

Obesity is considered as a serious public health epidemic problem all over the world and accompanied by adverse impacts on morbidity, mortality and quality of life of affected persons.<sup>1</sup> Its treatment include dietary programs, exercising, medical therapy, endoscopic procedures and surgery.<sup>2</sup> Medical treatment has been reported to be ineffective in the long-term treatment.<sup>1</sup>

Intra-gastric balloon has been shown to result in substantial weight reduction through generating a sense of fullness and reduces the volume available for food.<sup>3</sup> However, it has some complications, mostly related to the pressure effect and balloon rupture, including abdominal pain, nausea, vomiting, discomfort.<sup>4</sup>

Acute pancreatitis is a rare complication of intra-gastric balloon as a result of compression of the pancreas by intra-gastric balloon.<sup>5-10</sup> In this report, we present a rare case of acute pancreatitis complicating the insertion of intra-gastric balloon for female patient with morbid obesity.

### CASE PRESENTATION

A 20 years old female known case of hypothyroidism on thyroxin 75 mcg with past history of intra gastric balloon insertion on 16/9/2015 for weight reduction purposes which was fluid filled balloon. She presented to our Emergency department (ER) on 2/11/2015 complaining of sever epigastric pain radiating to back associated with nausea and vomiting aggravated by eating relieving by sitting down and leaning forward for one day

On examination, the patient was conscious oriented not pale or jaundiced, looked in pain with normal vital signs. Abdominal examination showed mild epigastric tenderness otherwise soft lax abdomen.


On investigations, serum glucose was 82 mg/dl (normal values 65-110 mg/dl) serum urea was 20 mg/dl (normal values 23-43 mg/dl), creatinine level was 0.7 mg/dl (normal values 0.8-1.3 mg/dl), sodium level was 137 mEq/L (normal values 135-145

### \*Correspondence to:

**Dr. Abdallah Mohammad Alferdaus,**  
Senior Registrar, General Surgery Department,  
Aseer Central hospital, Abha, Saudi Arabia.

### Article History:

Received: 11-07-2017, Revised: 29-07-2017, Accepted: 23-08-2017

Access this article online	
Website: <a href="http://www.ijmrp.com">www.ijmrp.com</a>	Quick Response code 
DOI: 10.21276/ijmrp.2017.3.5.060	

mEq/L), potassium level was 4.3mEq/L (normal values 3.5-5 mEq/L), total bilirubin was 0.2mg/dl (normal values 0.3-1 mg/dl), direct bilirubin was 0.1 mg/dl (normal values 0-0.4 mg/dl), alkaline phosphatase was 77U/L (normal values 30-100 U/L), gamma-glutamyl transferase was 30 U/L (normal values 6-50 U/L), amylase was 1328 U/L (normal values 30-125 U/L), SGPT was 24 (normal values 5-30 U/L), SGOT was 20 U/L (normal values 5-30 U/L) hemoglobin level was 13.4 g/dl (normal values 12-15 g/dl), WBC was 10.6x10<sup>9</sup>/L (normal 4-10 x10<sup>9</sup>/L), and platelet count was 405x10<sup>9</sup>/L (N 150-400 x10<sup>9</sup>/L).

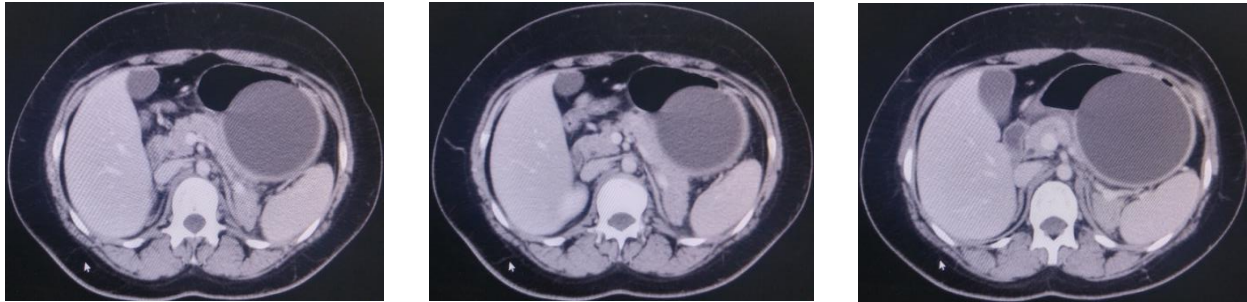
Ultrasound showed normal visualized gall bladder and biliary tree with no evidence of stones or sludge. The gastric balloon visualized filled fluid echogenicity material. Pancreas not visualized with horseshow kidneys. No other abnormality detected.

CT showed the tail of pancreas was mildly enlarged with surrounding fat stranding and normal pancreatic duct with normal gall bladder and biliary tree. Gastric balloon in the stomach and horse show kidneys were evident. No other abnormality detected. (Figure 1) Then the patient was managed conservatively as non-biliary pancreatitis and improved gradually then discharged in good condition. After about 6 months on 30/4/2016, the patient presented to our ER with similar symptoms and signs. Also she gave us a history of similar attack in between these two attacks on 14/12/2015, but she was away from the hospital so she didn't seek medical care and manage herself with analgesia and diet restriction then she improved. Her investigation were as follows; Glucose: 108 mg/dl, urea: 21 mg/dl, creatinine: 0.7 mg/dl, sodium: 131 mEq/L, potassium: 3.8 mEq/L, total. bilirubin: 0.5 mg/dl, direct bilirubin: 0.1mg/dl, SGPT: 23 U/L, SGOT: 15 U/L, alkaline phosphatase: 80 U/L, amylase: 923 U/L, gamma-glutamyl transaminase: 33 U/L, hemoglobin: 12.3 g/dl, WBC: 12.3x10<sup>9</sup>/L, and platelet count: 307x10<sup>9</sup>/L.

Ultrasound was done again and showed normal GB with no evidence of stones or sludge. Gastric balloon was in place. No other abnormality was detected.

Patient admitted again as non-biliary pancreatitis then we started thinking about relationship between the intra-gastric balloon and pancreatitis and we found some cases reported about that then

we discussed the issue with the patient and the family and they agreed to remove the balloon and it was removed on 3/5/2016. patient improved after that and discharged in good condition and followed after that for more than one year till 10/6/2017 and she was doing very well taking normal diet not complaining of any symptoms.



**Figure 1: CT showed the tail of pancreas was mildly enlarged with surrounding fat stranding and normal pancreatic duct with normal gall bladder and biliary tree. Gastric balloon in the stomach and horse show kidneys were evident.**

## DISCUSSION

Some researchers have evaluated the clinical efficacy and safety of the intra-gastric balloon as a non-surgical method for the management of morbid obesity.<sup>4,11,12</sup> Overall, it is commonly utilized procedure as it is less invasive and cheaper if compared to surgical therapy and more effective if compared to medical therapy.<sup>4,11-13</sup> Some of the studies were done on the efficacy of intra-gastric balloon. Some showed meaningful results in the form of reduction of body mass index by 5.3 -3.4 kg/m<sup>2</sup> and percentage total weight loss between 13.6% and 7.3%.<sup>14</sup> However others reported only 7.5% loss of starting body weight 6 months after balloon insertion.<sup>15</sup>

Although intra-gastric balloon is considered safe, it has some rare complications which are mostly tolerable by patients such as nausea, vomiting, abdominal cramps that occur mainly during the first week after insertion.<sup>16,17</sup> Some other complications were reported such as gastric perforation, bowel obstruction, gastroduodenitis, exacerbation of the ulcer, and worsening reflux oesophagitis.<sup>4,12,14</sup> Genco et al.<sup>12</sup> reported an overall rate of complication related to intra-gastric balloon insertion of 2.8%.

Few cases<sup>5-9</sup> worldwide including the present case reported pancreatitis as a complication of insertion of intra-gastric balloon. The pressure of the balloon on the pancreas was described as a reason of pancreatitis in most cases. This is most probably what happened also in the current case as removal of the balloon led to improvement of all patients' symptoms. The same has been reported by Öztürk et al<sup>7</sup> and Mohammed<sup>6</sup> who reported in addition, an improvement of amylase and CRP values.

In conclusion, intra-gastric balloon therapy is considered as a valid non-surgical mean for some patients, who failed to lose weight through other strategies. It is generally considered a safe weight reduction tool, despite few rare serious complication reports including pancreatitis. Therefore, it is necessary to keep these patients under close follow up and expect and identify these complications early to avoid a dramatic outcome. This case was reported because this up to our knowledge, the first one reported from Saudi Arabia and its reporting might increase physicians' awareness of this complication as symptoms of pancreatitis can be misdiagnosed as due to gastric distension by the balloon.

## REFERENCES

1. Tsigosa C, Hainerb V, Basdevant A, Finer N, Fried M, Mathus-Vliegen E, et al. Management of obesity in adults: European Clinical Practice Guidelines. *Obes Facts* 2008;1(2):106-16.
2. National Institutes of Health Internet. Bethesda, USA. How are overweight and obesity treated? Available from: <http://www.nhlbi.nih.gov/health/healthtopics/topics/obe/treatment.html>. Last updated February 23, 2017.
3. Peker Y, Coskun H, Bozkurt S, Cin N, Atak T, Genc H. Comparison of results of laparoscopic gastric banding and consecutive intra-gastric balloon application at 18 months: a clinical prospective study. *J Laparoendosc Adv Surg Tech A* 2011;21:471-5.
4. Imaz I, Martínez-Cervell C, García-Alvarez EE, Sendra-Gutiérrez JM, González-Enríquez J. Safety and effectiveness of the intra-gastric balloon for obesity. A meta-analysis. *Obes Surg* 2008;18:841-6.
5. Banks PA, Bollen TL, Dervenis C, et al. Classification of acute pancreatitis--2012: revision of the Atlanta classification and definitions by international consensus. *Gut* 2013;62(1):102-11.
6. Mohammed AE, Benmoussa A. Acute pancreatitis complicating intra-gastric balloon insertion. *Case Rep Gastroenterol* 2008 Sep 20;2(3):291-5.
7. Öztürk A, Yavuz Y, Atalay T. A case of duodenal obstruction and pancreatitis due to intra-gastric balloon. *Balkan Med J* 2015;32:323-6.
8. Torres OJM, Moraes-Junior JMA, Torres CCS, Nunes EAN. Acute pancreatitis due to intra-gastric balloon. *Int J Case Rep Images* 2016;7(8):499-502.
9. Issa I, Taha A, Azar C. Acute pancreatitis caused by intra-gastric balloon: A case report. *Obes Res Clin Pract.* 2016 May-Jun;10(3):340-3.
10. Said F, Robert S, Mansour E. Pancreatitis and intra-gastric balloon insertion. *Surgery for Obesity and Related Diseases* 2016; 12(3):e33-e34.
11. Ramadan MEA, Abdel Hamid HK, Ramadan AR, Abdel Kader AR. Bioenterics Intra-gastric Balloon: Safety, Tolerance, and Efficacy of 6 months Balloon Treatment: Egyptian Experience with 50 patients. *N Y Sci J* 2014;7:6-9.

12. Genco A, Bruni T, Doldi SB, Forestieri P, Marino M, Busetto L, et al. Bioenterics intra-gastric balloon: The Italian experience with 2515 patients. *Obes Surg* 2005;15:1161-4.
13. Mathus-Vliegen EM. Intra-gastric balloon treatment for obesity: what does it really offer? *Dig Dis* 2008;26:40-4.
14. Sallet JA, Marchesini JB, Paiva DS et al. Brazilian multicenter study of the intra-gastric balloon. *Obes Surg* 2004;14(7):991-8.
15. Ganesh R, Rao AD, Baladas HG, Leese T. The Bioenteric Intra-gastric Balloon (BIB) as a treatment for obesity: poor results in Asian patients. *Singapore Med J* 2007;48:227-231.
16. Giardiello C, Borrelli A, Silvestri E, Antognozzi V, Iodice G, Lorenzo M. Air-filled vs water-filled intra-gastric balloon a prospective randomized study. *Obes Surg* 2012; 22(12):1916-9.
17. Machytka E, Klvana P, Kornbluth A, Pelkin S, Mathus-Vliegen LE, Gostout C, et al. Adjustable intra-gastric balloons a 12-month pilot trial in endoscopic weight loss management. *Obes Surg* 2011; 21(10):1499-507.

**Source of Support:** Nil.

**Conflict of Interest:** None Declared.

**Copyright:** © the author(s) and publisher. IJMRP is an official publication of Ibn Sina Academy of Medieval Medicine & Sciences, registered in 2001 under Indian Trusts Act, 1882.

This is an open access article distributed under the terms of the Creative Commons Attribution Non-commercial License, which permits unrestricted non-commercial use, distribution, and reproduction in any medium, provided the original work is properly cited.

**Cite this article as:** Abdulrahman Mohammed Abu Alqasim, Abdallah Mohammad Alferdaus, Toriki Maed Alsalem. Acute Pancreatitis Induced by Intra-gastric Balloon. *Int J Med Res Prof.* 2017 Sept; 3(5):309-11. DOI:10.21276/ijmrp.2017.3.5.060