

Intracranial Infections and the Neurosurgeon: A Clinico-Microbiological Study and the Management Perspective

Jasdeep Singh^{1*}, Bhagirath More¹, Tushar Soni², Amisha Sidhu¹

¹Senior Resident, ²Professor and Unit Head, Department of Neurosurgery, N. H. L. Municipal Medical College and Sheth V. S. Hospital, Ahmedabad, Gujarat, India.

ABSTRACT

Introduction: In Intracranial Suppurative Infection patients, the infectious process attacks the CNS, which is incapable of exerting a significant immune defense generally leading to subdural empyema due to breach of the duramater. The aim of this work is to study the current concepts regarding epidemiology, pathophysiology, etiology, clinical presentation, diagnosis, and management of Central nervous system (CNS) infections.

Materials and Methods: The present data was collected from patients who had been diagnosed with Intracranial Suppurative Infection. All the cases were managed by a single surgeon to rule out variability in technical aspects. Patients were retrospectively evaluated by review of the data, including physical examination, laboratory (biochemistry and microbiology) testing, and radiological examination collected.

Results: Orogenic infection has been found to be the most common source of Intracranial Suppurative Infection, followed by sinusitis infection. Orogenic infections are associated with temporal and cerebellar abscess while sinusitis is generally associated with frontal abscess. One patient had CSF, rhinorrhea, managed conservatively. Two patients had wound gaping in craniotomy group, for which secondary suturing was done. 21 specimens yielded microbial flora of which Staph aureus and Streptococcus sp. were of equal frequency (7 cases each) followed by Pseudomonas(4 cases) and Enterococcus avium (3 cases). All Subdural empyema cases (50 cases) underwent craniotomy, burr hole and aspiration in

11 cases, re exploration was done in 3 cases, external ventricular drain in 7 cases and ventriculo peritoneal shunt in 2 cases.

Conclusion: Delayed diagnosis of Intracranial Suppurative Infection, rapid progression, coma, multiple lesions, intraventricular rupture, lower Glasgow coma score at admission, have been reported as poor prognostic factors. Brain abscess excision has better results in the form of shorter hospital stay, short duration of antibiotic coverage and patient outcome, compared to aspiration but in deep seated lesions, one can go for aspiration to prevent neurological deficit.

Keywords: Infection; Intracranial; Neurosurgery; Suppurative.


*Correspondence to:

Dr. Jasdeep Singh,
Senior Resident,
Department of Neurosurgery,
N. H. L. Municipal Medical College,
Ahmedabad, Gujarat, India.

Article History:

Received: 14-08-2018, Revised: 10-09-2018, Accepted: 28-09-2018

Access this article online

Website: www.ijmrp.com	Quick Response code 
DOI: 10.21276/ijmrp.2018.4.5.061	

INTRODUCTION

In Intracranial Suppurative Infection patients, the infectious process attacks the CNS, which is incapable of exerting a significant immune defense generally leading to subdural empyema due to breach of the duramater.¹ Trepanation is known to be the first surgical procedure ever performed² and Sir Percival Pott was probably the first to recognize and document that infections elsewhere in the body could spread and cause Brain Abscess.³

40% of infections are cryptic in origin, 25-50% are pericranial contiguous focus, 15-30% are hematogenous spread, 8-19% are direct inoculation and from oral cavity, hematogenous spread (intra-abdominal/pelvic infections), and from otorhinolaryngeal infections the commonest organisms isolated are anaerobic

pathogens.⁴ CNS infections primarily present in four basic syndromes i.e. focal mass expansion, intra cranial hypertension, diffuse destruction and focal neurological deficit.³ The penetration of antimicrobial drugs from the systemic circulation into brain tissue is complex; the physiological properties of the blood-brain barrier and the blood-CSF barrier are distinct. Thus, the penetration of drugs into CSF differs from that into brain tissue or intracranial pus.⁵

After the introduction of antibiotics, organism-isolation techniques, and computed tomography (CT), Rosenblum et al⁶ reported 0% mortality in a series of 20 patients in 1978. Infectious diseases are usually common in tropical countries.⁷ Although, there have been breakthrough advances in neuroimaging, neuroanaesthesia,

microbiological isolation techniques, and antibiotic therapy, neurosurgical techniques, CNS infections can be fatal.⁸ According to the "Infection in Neurosurgery' Working Party Of The British Society For Antimicrobial Chemotherapy," the guiding principles for surgical management are to urgently reduce raised intracranial pressure by aspiration of the cavity using image guidance, to confirm the diagnosis, to obtain pus for microbiological diagnosis, to enhance the efficacy of antibiotic therapy and to avoid iatrogenic spread of infection into the ventricles.³

Sargent, in 1928, was the first to report successful excision of Brain Abscess.⁸ The historical methods of surgical drainage have been tube drainage, marsupialization, the migration method of Kahn, and Dandy's sequential tapping of a chronic Brain Abscess to prevent brain fungus coinfection. Currently, the principal methods for surgical management are open evacuation, excision, or aspiration through a burr hole and more recently stereotactic.⁹ The aim of this work is to review the current concepts regarding epidemiology, pathophysiology, etiology, clinical presentation, diagnosis, and management of Central nervous system (CNS) infections.

MATERIALS AND METHODS

The present data was collected from patients who had been diagnosed with Intracranial Suppurative Infection and followed up at the Neurosurgery Department at NHL Municipal Medical College and VS General Hospital between 2008 to 2016. All the cases were managed by a single surgeon to rule out variability in technical aspects.

Inclusion Criteria was Characteristic Computed Tomography (CT)/Magnetic Resonance Imaging (MRI) findings, Evidence of bacterial brain abscess from surgery, Clinical history and Treatment response compatible with intracranial suppurative infection in patients with negative microbial findings. Tubercular, Parasitic and Fungal lesions have been excluded from the study. Patients were retrospectively evaluated by review of the data, including physical examination, laboratory (biochemistry and microbiology) testing, and radiological examination collected.

Review of the findings and specimen testing of the patients were performed to confirm diagnosis.

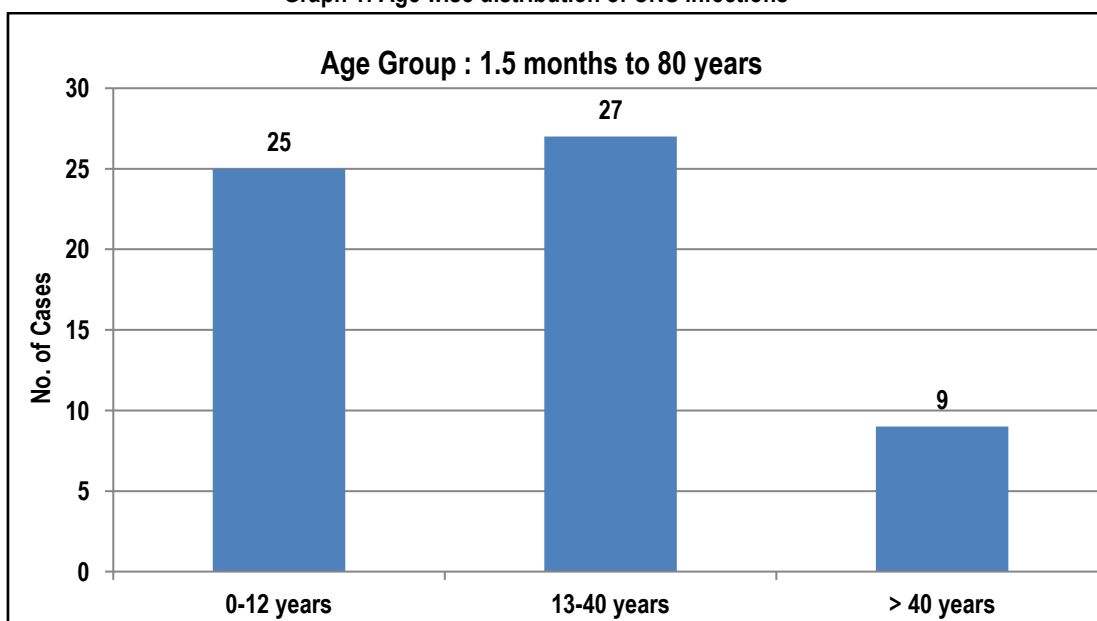
On admission patients were subjected to routine investigations including CBC, Peripheral Smear examination, Se Electrolytes, LFT and RFT, Urine Routine, Blood Sugar examination, USG Abdomen and Pelvis, X-ray Chest examination, Fundus examination. 2 D Echo or Bedside Vscan was done to rule out congenital heart disease. ENT department reference was done to rule out any Otorhinologic infection.

RESULTS

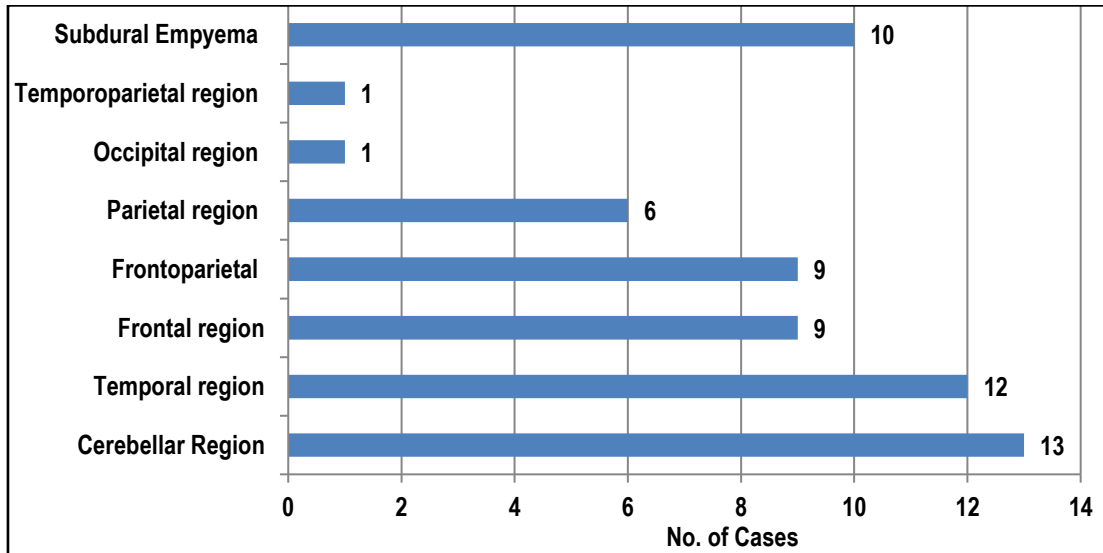
A total of 61 patients were included in the study, 45 male and 16 female. Graph 1 shows age wise distribution. Graph 2 shows location wise distribution of CNS infections. Otogenic infection has been found to be the most common source of Intracranial Suppurative Infection, followed by sinusitis infection. Otogenic infections are associated with temporal and cerebellar abscess while sinusitis is generally associated with frontal abscess (graph 2). Graph 3 shows clinical presentation of Glasgow outcome scale i.e. dead in nil cases, persistent vegetative state in nil cases, severe disability in 1, moderate disability in 4 and good recovery in 56. One patient had growing skull fracture (dura was left open and the osteoplastic flap was placed). Graph 4 shows clinical symptoms and graph 5 shows comorbidities in cases with CNS infections.

One patient had CSF, rhinorrhea, managed conservatively. Two patients had wound gaping in craniotomy group, for which secondary suturing was done. 21 specimens yielded microbial flora of which Staph aureus and Streptococcus sp. were of equal frequency (7 cases each) followed by Pseudomonas(4 cases) and Enterococcus avium (3 cases) (graph 6). Table 1 shows operative intervention, all Subdural empyema cases (50 cases) underwent craniotomy, burr hole and aspiration in 11 cases, re exploration was done in 3 cases, external ventricular drain in 7 cases and ventriculo peritoneal shunt in 2 cases. Persistent fever, lack of regression in the size of the abscess, deterioration of signs and symptoms, appearance of cranial nerve deficits or seizures may indicate failure of therapy.

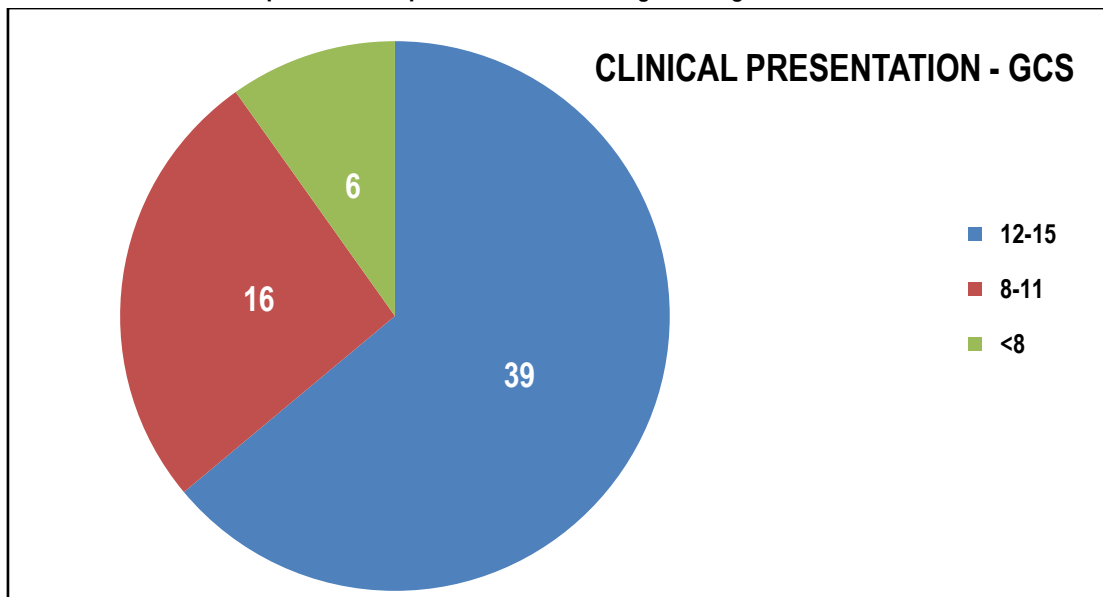
Graph 1: Age wise distribution of CNS infections



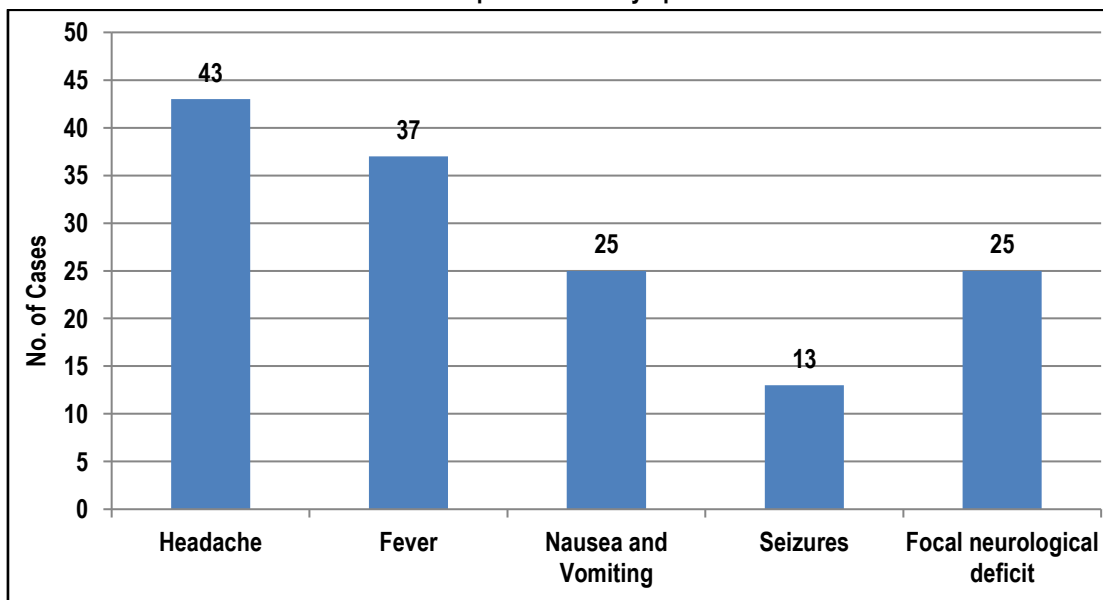
Graph 2: Location wise distribution of CNS infections



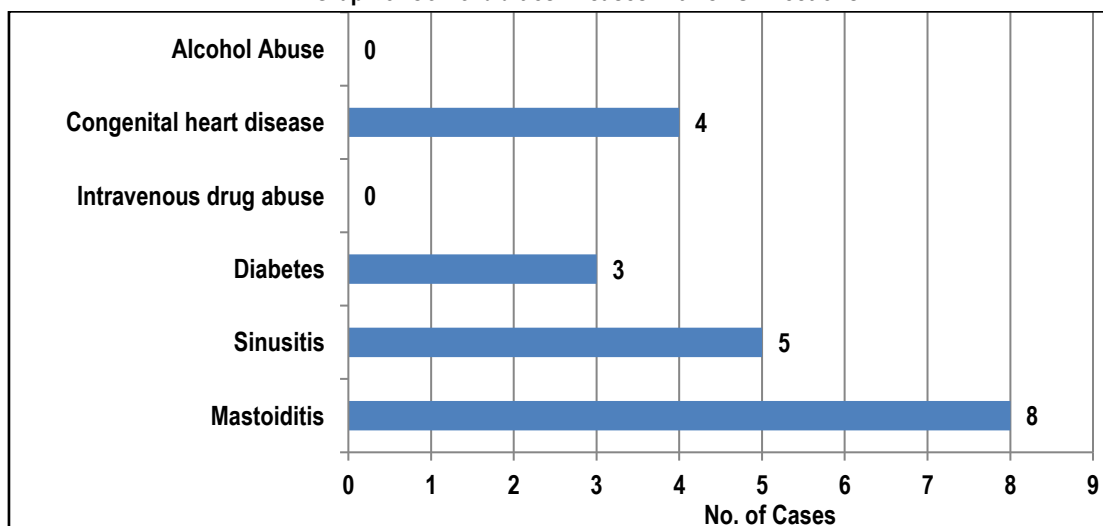
Graph 3: Clinical presentation according to Glasgow Outcome Scale



Graph 4: Clinical symptoms



Graph 5: Comorbidities in cases with CNS infections



Graph 6: Graphic presentation of microbial culture of CNS cases

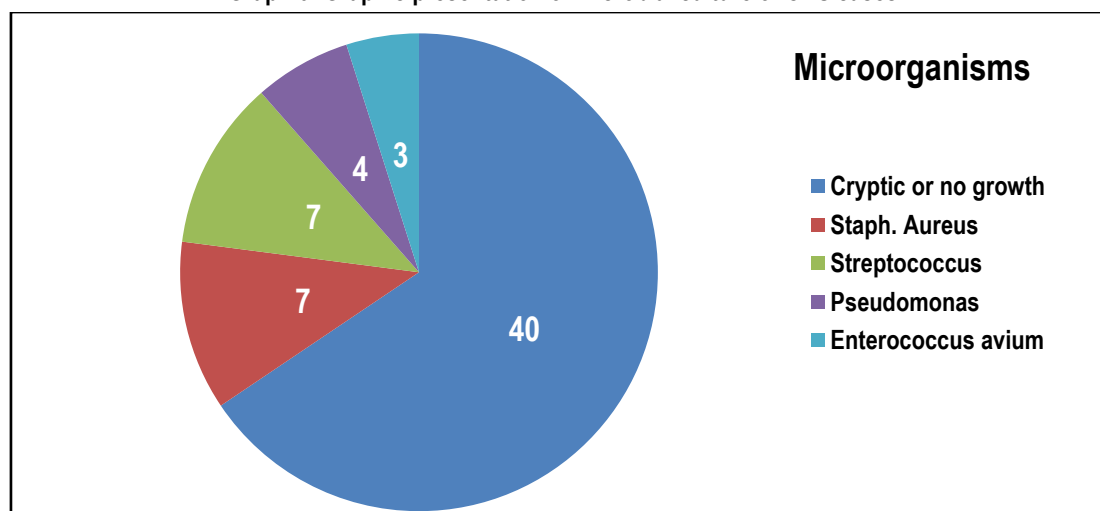


Table 1: Operative intervention of CNS cases

Operative intervention	No. of cases
Craniotomy (All Subdural empyema cases underwent craniotomy)	50
Burr hole and aspiration	11
Re exploration	3
External Ventricular Drain	7
Ventriculo peritoneal Shunt	2

Table 2: Comparison of present study with Study by Y. Taner et al¹³

Parameters`	Present Study	Study by Y. Taner et al
Total No. of Cases	61	23
Males	45	17
Females	16	6
Age Range	1.5 months to 80 years	19-67 years
Invasive Procedure	Patients with operative intervention	16 Patients
Mortality	Nil	2 cases
Most Common Symptoms	Headache	Headache
Comorbidity	Mastoiditis	Mastoiditis
Location	Cerebellar followed by temporal region	Frontal region
Positive Culture	21 Cases	6 cases out of 16 cases
Re-exploration	3 cases in burrhole aspiration twice	3 cases in burrhole aspiration twice

Table 3: Comparison of present study with various other studies

	Total Cases	BA Capsule Excision	BA Aspiration	Residual / Recurrence	Hospital Stay (BA Capsule Excision / BA Aspiration)	Antibiotic uses (BA Capsule Excision / BA Aspiration)
Our Study	51 cases of BA(10 cases in Empyema group)	40 cases	11 cases	3 cases	21.2 days / 34.4 days	2.9 weeks / 3.7 weeks
Mut et al¹⁴	20	9	11	3 cases in aspiration group	22.4 days / 46.6 days	26.7 days / 46.6 days in aspiration group
Tan et al¹⁵	51	28	23	11 patients in aspiration group. 8 re-aspiration, 3 craniotomy & 1 patient in craniotomy group	-	-
Sarmast et al¹⁶	47	18	29	6 cases in aspiration group	18.1 days / 24.9 days	2.7 weeks / 3.8 weeks

DISCUSSION

In the present study, most reported cases occur in young to adult group. Fever and headache, which are also the main signs of acute bacterial meningitis, should be considered in the differential diagnosis of Intracranial Suppurative Infection. Lumbar puncture should be avoided in patients who have neurological findings, headache and papilloedema owing to its hazards, including uncal herniation, rupture of an abscess cavity into the ventricle, etc.¹⁰ CT which is crucial for early and differential diagnosis could be performed at admission in the emergency room. CT has also been found also useful for follow-up of patients. MRI is more sensitive for early cerebritis, detecting satellite lesions, estimating the extent of central necrosis, ring enhancement, and cerebral edema and visualizing the brainstem compared with CT. Especially diffusion-weighted MRI can differentiate ring-enhancing lesions due to brain abscess from neoplastic lesions.¹¹Otogenic infection has been found to be the most common source of Intracranial Suppurative Infection, followed by sinusitis infection. Otogenic infections are associated with temporal and cerebellar abscess while sinusitis is generally associated with frontal abscess. 21 specimens yielded microbial flora of which Staph aureus and Streptococcus sp. were of equal frequency (7 cases each) followed by Pseudomonas(4 cases) and Enterococcus avium (3 cases). Sampling under antibiotic treatment is more likely to be related to low positive culture rates. Treatment of Intracranial Suppurative Infection should be based on antimicrobial therapy active against possible causative pathogens and able to penetrate the blood-brain barrier.¹² Ceftriaxone combined with Metronidazole was started as empirical therapy. Although some patients needed escalated therapy including Vancomycin and Meropenem. Patients were treated with IV antimicrobial therapy for 18- 21 days in whom Brain Abscess excision was done. A patient's history of neurosurgical operation; infection with resistant bacteria, such as methicillin-resistant *S. aureus*, and admission from settings with high antimicrobial resistance rates should be taken into consideration when selecting an antimicrobial therapy. Table 2 shows comparison of present study with study by Yildirmak T et al.¹³ Mut et al¹⁴ carried a study with aim of aspiration of the abscess cavity versus excision of capsule are still in debate for the

capsulated, large, superficially located abscesses. Nine patients underwent the capsule excision and 11 patients had the aspiration of their abscesses. There were no differences in terms of age, sex, location of abscesses, and radiographic features. There were 3 residual/recurrence in the aspiration group, who needed a second aspiration whereas; no residual/recurrence was observed in the excision group. Postoperative utilization of antibiotics was significantly less in the excision group (Mean: 26.7 days in the excision group vs. 46.6 days in aspiration group). Length of hospital stay for the purpose of iv antibiotic administration was significantly shorter in the excision group in close correlation with iv antibiotic use. This study demonstrated that excision of abscess capsule was superior to aspiration in terms of efficiency of surgical intervention and postoperative cost of the treatment in a highly selected group of brain abscesses. Tan WM et al¹⁵ compared the two surgical methods (burr hole and craniotomy) used as treatment for superficial cerebral abscess and its outcome in terms of radiological clearance on brain CT, improvement of neurological status, the need for repeated surgery, and survival and morbidity at three months after surgery and the study revealed that patients who had undergone craniotomy and excision of abscess showed a significantly earlier improvement in neurological function, better radiological clearance and lower rate of re-surgery as compared to the burr hole aspiration group (P<0.05). However, with respect to neurological improvement at 3 months, morbidity and mortality, there was no significant difference between the two surgical methods. Table 3 shows comparison of present study with various other studies.¹⁴⁻¹⁶ Arlotti et al¹⁷ in their systematical review of the literature regarding controversial aspects of Brain Abscess management, found that there is insufficient evidence to make specific recommendations for antibacterial treatment for Brain Abscess. Our findings indicate that Intracranial Suppurative Infection patients should be evaluated to identify the source of the infection and a means of surgical intervention that can achieve a cure without relapse or sequelae. Although relapse did not occur among our cases, it has been reported in patients who have undergone surgical intervention and inadequate therapy.

CONCLUSION

Delayed diagnosis of Intracranial Suppurative Infection, rapid progression, coma, multiple lesions, intraventricular rupture, lower Glasgow coma score at admission, have been reported as poor prognostic factors. Brain abscess excision has better results in the form of shorter hospital stay, short duration of antibiotic coverage and patient outcome, compared to aspiration but in deep seated lesions, one can go for aspiration to prevent neurological deficit.

We also recommend that male patients with headache and neurological signs and symptoms, whether with or without fever, be evaluated for Intracranial Suppurative Infection on admission for early diagnosis and provision of timely, adequate therapy and, if necessary, surgical intervention to reduce mortality and sequelae rates.

REFERENCES

1. Britt RH, Enzmann DR, Yeager AS. Neuropathological and computerized tomographic findings in experimental brain abscess. *Journal of neurosurgery*. 1981 Oct;55(4):590-603.
2. Kumar A, Saeed H, Alamri A, Crocker M, Dave J. Twenty years of intracranial abscesses: prognostic indicators and treatment review. *Journal of Infection*. 2011 Dec 1;63(6):491-2.
3. Miranda HA, Castellar-Leones SM, Elzain MA, Moscote-Salazar LR. Brain abscess: current management. *Journal of neurosciences in rural practice*. 2013 Aug;4(Suppl 1):S67.
4. Bhatia R, Tandon PN, Banerji AK: Brain abscess - an analysis of 55 cases. *Int Surg* 1973, 58: 565-568.
5. Nau R, Sorgel F, Eiffert H. Penetration of drugs through the blood-cerebrospinal fluid/blood-brain barrier for treatment of central nervous system infections. *Clin Microbiol Rev*. 2010;23(4):858-83.
6. Rosenblum SB, Huynh T, Afonso A, Davis HR, Yumibe N, Clader JW, Burnett DA. Discovery of 1-(4-fluorophenyl)-(3 R)-[3-(4-fluorophenyl)-(3 S)-hydroxypropyl]-(4 S)-(4-hydroxyphenyl)-2-azetidinone (SCH 58235): a designed, potent, orally active inhibitor of cholesterol absorption. *Journal of medicinal chemistry*. 1998 Mar 12;41(6):973-80.
7. Wiwanitkit S, Wiwanitkit V. Pyogenic brain abscess in Thailand. *North American journal of medical sciences*. 2012 Jun;4(6):245.
8. Muzumdar D, Jhavar S, Goel A. Brain abscess: an overview. *International journal of surgery*. 2011 Jan 1;9(2):136-44.
9. Nathoo N, Narotam PK, Nadvi S, van Dellen JR. Taming an old enemy: a profile of intracranial suppuration. *World neurosurgery*. 2012 Mar 1;77(3-4):484-90.

10. Hall WA, Truwit CL. The surgical management of infections involving the cerebrum. *Neurosurgery*. 2008;62(suppl 2):519-30.
11. Martin G. The death of Henry II of France: a sporting death and post-mortem. *ANZ J Surg*. 2001;71:318-20.
12. Sjölin J, Lilja A, Eriksson N, Arneborn P, Cars O. Treatment of brain abscess with cefotaxime and metronidazole: prospective study on 15 consecutive patients. *Clinical infectious diseases*. 1993 Nov 1;17(5):857-63.
13. Yıldırım T, Gedik H, Şimşek F, Kantürk A. Community-acquired intracranial suppurative infections: A 15-year report. *Surgical neurology international*. 2014;5.
14. Mut M, Hazer B, Narin F, Akalan N, Ozgen T. Aspiration or capsule excision? Analysis of treatment results for brain abscesses at single institute. *Turk Neurosurg*. 2009;19:36-41.
15. Tan WM, Adnan JS, Mohamad Haspani MS. Treatment outcome of superficial cerebral abscess: An analysis of two surgical methods. *Malays J Med Sci*. 2010;17:23-9
16. Sarmast A, Showkat H, Kirmani A, Bhat A, Patloo A, Ahmad S, et al. Aspiration versus excision: A single center experience of Forty-Seven patients with brain abscess over 10 years. *Neurol Med Chir (Tokyo)* 2012;52:724-30.
17. Arlotti M, Grossi P, Pea F, Tomei G, Vullo V, De Rosa FG, Di Perri G, Nicastrì E, Lauria FN, Carosi G, Moroni M. Consensus document on controversial issues for the treatment of infections of the central nervous system: bacterial brain abscesses. *International Journal of Infectious Diseases*. 2010;14:S79-92.

Source of Support: Nil. **Conflict of Interest:** None Declared.

Copyright: © the author(s) and publisher. IJMRP is an official publication of Ibn Sina Academy of Medieval Medicine & Sciences, registered in 2001 under Indian Trusts Act, 1882. This is an open access article distributed under the terms of the Creative Commons Attribution Non-commercial License, which permits unrestricted non-commercial use, distribution, and reproduction in any medium, provided the original work is properly cited.

Cite this article as: Jasdeep Singh, Bhagirath More, Tushar Soni, Amisha Sidhu. Intracranial Infections and the Neurosurgeon: A Clinico-Microbiological Study and the Management Perspective. *Int J Med Res Prof*. 2018 Sept; 4(5): 269-74. DOI:10.21276/ijmrp.2018.4.5.061