

# Adverse Drug Reactions of Tyrosine Kinase Inhibitors in the Treatment of Advanced Lung Cancer

Pankaj Tantia<sup>1</sup>, Ritika Agarwal<sup>2\*</sup>, Jitendra Acharya<sup>3</sup>

<sup>1</sup>M.D. (General Medicine), Fellowship in Bone Marrow Transplantation, Senior Resident, Department of Medical Oncology, S.P. Medical College, Bikaner Rajasthan, India.

<sup>2\*</sup>Senior Demonstrator, Department of Pathology, S.P. Medical College, Bikaner Rajasthan, India.

<sup>3</sup>Senior Demonstrator, Department of Dentistry, S.P. Medical College, Bikaner Rajasthan, India.

## ABSTRACT

**Introduction:** Erlotinib and gefitinib are the most commonly used epidermal growth factor receptor - tyrosine kinase inhibitors (EGFR - TKIs) in the treatment of EGFR mutant nonsmall cell lung cancer (NSCLC). Both erlotinib and gefitinib have shown equal efficacy in terms of response rates and overall survival. Hence, their toxicity profile becomes the most important determining factor in choosing these agents when treating EGFR mutant NSCLC. In this study, we compared the toxicity profile of erlotinib and gefitinib among an Indian subset of lung cancer patients.

**Materials and Methods:** In this prospective nonrandomized study, 85 patients came at Acharya Tulsi Regional Cancer Treatment & Research Institute with NSCLC were tested for EGFR mutation status, and EGFR mutant patients were started on either erlotinib or gefitinib. They were periodically monitored for drug toxicities.

**Results:** Out of the 85 patients tested, 34 patients were positive for EGFR mutation. Eleven of them were started on erlotinib and 23 were started on gefitinib. The most common side effect of TKIs was skin rash. Nine out of the 11 patients started on erlotinib and 7 of the 23 patients started on gefitinib had skin rash. Grade 3 and 4 skin rash was significantly more among patients treated with erlotinib which resulted in treatment delays. Other side effects of TKIs such as diarrhea

and deranged liver functions were similar among the both subsets of patients.

**Conclusion:** Skin toxicity is the major and serious side effect with erlotinib among Indian patients with EGFR mutant lung cancer. This resulted in significant treatment delay, which might adversely affect the overall survival of patients. Gefitinib was better tolerated and had a safer toxicity profile compared to erlotinib in Indian patients.

**Keywords:** Epidermal Growth Factor Receptor, Tyrosine Kinase Inhibitor, Skin Toxicity, Treatment Delay.


## \*Correspondence to:

Dr. Ritika Agarwal,  
Senior Demonstrator,  
Department of Pathology,  
S.P. Medical College, Bikaner Rajasthan, India.

## Article History:

Received: 17-08-2018, Revised: 11-09-2018, Accepted: 29-09-2018

## Access this article online

Website: <a href="http://www.ijmrp.com">www.ijmrp.com</a>	Quick Response code 
DOI: 10.21276/ijmrp.2018.4.5.064	

## INTRODUCTION

Epidermal growth factor receptor - tyrosine kinase inhibitors (EGFR - TKIs) have become the standard of care in the management of EGFR mutant lung cancers. Compared to chemotherapeutic agents, EGFR - TKIs have proven their superiority in terms of survival and toxicity profile when treating nonsmall cell lung cancer (NSCLC) patients positive for EGFR mutation.<sup>1-4</sup> With the exception of leptomeningeal metastasis where erlotinib has shown better response than gefitinib, both of these TKIs are equally efficient when treating EGFR mutant NSCLC.<sup>5-6</sup> Hence, safer toxicity profile becomes one of the most important factors when choosing these TKIs. In this study, we compared the different toxicity profiles of erlotinib and gefitinib among Indian population.

## MATERIALS AND METHODS

Eighty-five patients came at Acharya Tulsi Regional Cancer Treatment & Research Institute were screened for EGFR mutation, at our Institute, Bikaner India.

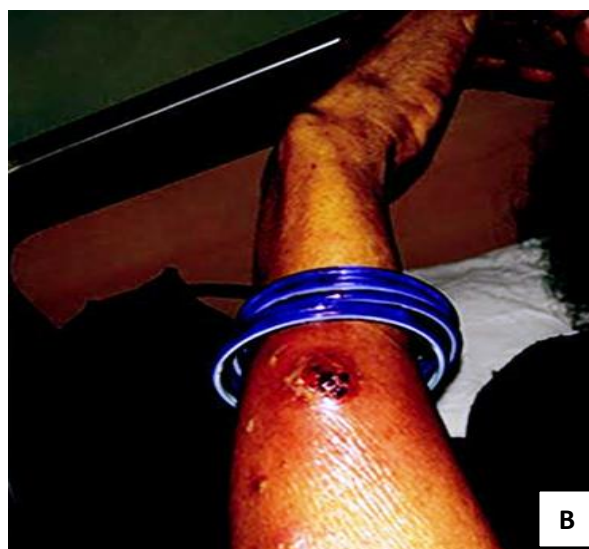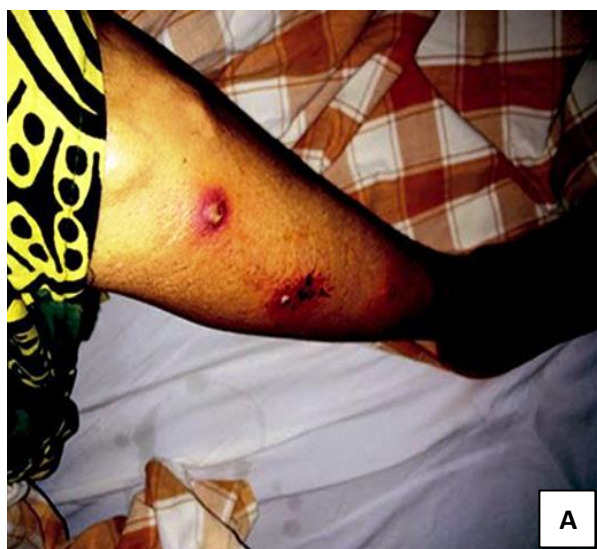Patients were started on either erlotinib 150 mg or gefitinib 250 mg in the first-line setting based on physician discretion. Patients were followed up for every month till disease progression. Detailed history and physical examination with special emphasis on drug toxicity was performed at every visit. Toxicity of TKIs was graded according to the National Cancer Institute Common Terminology Criteria for Adverse Events v 4.0.<sup>7</sup> Institutional ethical clearance was obtained prior to the study. All were informed regarding the study and written consent was obtained.

**Table 1: Demographic profile of patients on TKI's therapy**

Particular	Erlotinib	Gefitinib
<b>Male</b>	7	14
<b>Female</b>	4	9
<b>Median age</b>	53	56
<b>Performance status</b>		
0-1	8	18
2-4	3	5
<b>Smoking</b>		
Yes	3	5
No	8	18
<b>EGFR mutation status</b>		
Positive	10	21
Negative	1	2

**Table 2: Toxicity profile of patients treated with TKI's**

Particular	Erlotinib	Gefitinib
<b>Skin rash</b>	9	7
<b>Grade 3-4 skin rash</b>	5	1
<b>diarrhea</b>	2	2
<b>Interstitial fibrosis/ILD</b>	0	1
<b>Mucositis</b>	2	2
<b>Increased SGOT/SGPT(&gt;5 ULN)</b>	1	2
<b>Hand foot syndrome</b>	1	1
<b>Conjunctivitis</b>	0	1



**Figure 1(A,B): Erlotinib-induced pustular skin lesions affecting face, leg, and hand**

**RESULTS**

Total 85 patients tested for EGFR mutation, 34 (40%) patients were positive for the same. Twenty three patients were started on gefitinib and 11 patients were started on erlotinib. Demographic profile of patients started on TKIs is shown in Table 1.

Skin toxicity was the major side effect of TKIs. Nine of the 11 patients treated with erlotinib had skin toxicity compared to 7 of the 23 patients treated with gefitinib. Grade 3–4 skin toxicity was observed in five patients among erlotinib arm compared to only

one patient among gefitinib arm. Of the nine patients who developed skin rash with erlotinib, four required dose reduction from 150 mg to 100 mg. In four patients, erlotinib was changed to gefitinib, as reducing the dose did not result in decrease in skin toxicities [Figure 1]. Gefitinib-induced drug rash was managed conservatively with antihistamines and clindamycin skin ointment without treatment interruption. Other side effects such as diarrhea and deranged liver function were comparable in both the groups as shown in Table 2.

## DISCUSSION

Randomized studies have clearly shown survival benefit of TKIs compared to chemotherapy when treating EGFR mutated lung cancer.<sup>1-4</sup> TKIs such as erlotinib and gefitinib used in the treatment of EGFR mutated lung cancer have similar toxicity profiles, but the grades and severity of the toxicities have not been studied extensively. In this prospective study, we compared toxicity profile of erlotinib and gefitinib in Indian patients.

In our study, skin toxicity was the most important side effect with erlotinib compared to gefitinib. Nine of the 11 patients treated with erlotinib had skin toxicity with five of them having Grade 3–4 skin rash (45.45%) whereas only 7 of the 23 patients treated with gefitinib had skin toxicity and only one among them had Grade 3–4 skin rash. Grade 3–4 toxicity due to erlotinib in our study was much higher than that found in OPTIMAL and EURTAC studies (2% and 13%, respectively).<sup>3,4</sup> This probably is because the steady-state plasma trough concentration by erlotinib at its maximal tolerated dose of 150 mg was 3.5 times higher than that produced by gefitinib at its approved dose of 250 mg once daily which was approximately one-third of the maximum tolerated dose.<sup>8-9</sup>

Because of the skin toxicity, erlotinib dose was reduced to 100 mg in four patients which they could tolerate, and for the other four patients, erlotinib was changed to gefitinib as their skin toxicity recurred with the same severity even following dose reduction. All these four patients tolerated gefitinib well and three of them had Grade 1 rash. In only one patient, erlotinib was continued at 150 mg after treating skin rash with antihistamines and clindamycin topical ointment. There was a significant delay in the treatment in erlotinib arm due to skin toxicity. Treatment had to be stopped for at least 20 days in six of the patients until the rash subsided.

In the gefitinib arm, there were no treatment delays and Grade 2–3 rash was managed with antihistamines and clindamycin topical ointments. Other side effects such as diarrhea, deranged liver function test, and hand foot syndrome were comparable in both arms.

The limitation of our study is small sample size. This study can be taken as a pilot study for planning bigger randomized studies.

## CONCLUSION

Skin toxicity is a major side effect with erlotinib among Indian patients which results in significant treatment delay, which in turn may adversely affect the survival of patients with EGFR mutant lung cancer. Dose reduction and changing the drug were helpful in patients who could not tolerate 150 mg of erlotinib. Gefitinib had a much more friendly toxicity profile and was well tolerated among Indian patients.

## REFERENCES

1. Maemondo M, Inoue A, Kobayashi K, Sugawara S, Oizumi S, Isobe H, et al. Gefitinib or chemotherapy for non-small cell lung cancer with mutated EGFR. *N Engl J Med* 2010;362:2380–8.

2. Mitsudomi T, Morita S, Yatabe Y, Negoro S, Okamoto I, Tsurutani J, et al. Gefitinib versus cisplatin plus docetaxel in patients with non-small-cell lung cancer harbouring mutations of the epidermal growth factor receptor (WJTOG3405): An open label, randomised phase 3 trial. *Lancet Oncol* 2010;11:121–8.

3. Zhou C, Wu YL, Chen G, Feng J, Liu XQ, Wang C, et al. Erlotinib versus chemotherapy as first line treatment for patients with advanced EGFR mutation positive non-small cell lung cancer (OPTIMAL, CTONG 0802): A multicentre, open label, randomised, phase 3 study. *Lancet Oncol* 2011;12:735–42.

4. Rosell R, Carcereny E, Gervais R, Vergnenegre A, Massuti B, Felip E, et al. Erlotinib versus standard chemotherapy as first line treatment for European patients with advanced EGFR mutation positive non-small cell lung cancer (EURTAC): A multicentre, open label, randomised phase 3 trial. *Lancet Oncol* 2012;13:239–46.

5. Wu WS, Chen YM, Tsai CM, Shih JF, Chiu CH, Chou KT, et al. Erlotinib has better efficacy than gefitinib in adenocarcinoma patients without EGFR activating mutations, but similar efficacy in patients with EGFR activating mutations. *Exp Ther Med* 2012;3:207–13.

6. Lee E, Keam B, Kim DW, Kim TM, Lee SH, Chung DH, et al. Erlotinib versus gefitinib for control of leptomeningeal carcinomatosis in non-small cell lung cancer. *J Thorac Oncol* 2013;8:1069–74.

7. National Institutes of Health. National Cancer Institute. Common Terminology Criteria for Adverse Events (CTCAE); Version 4.0 Published: May 28, 2009 (v4.03: June 14, 2010). 2010.

8. Li J, Karlsson MO, Brahmer J, Spitz A, Zhao M et al. CYP3A phenotyping approach to predict systemic exposure to EGFR tyrosine kinase inhibitors. *J Natl Cancer Inst* 2006;98:1714–23.

9. Tan AR, Yang X, Hewitt SM, Berman A, Lepper ER, Sparreboom A, et al. Evaluation of biologic end points and pharmacokinetics in patients with metastatic breast cancer after treatment with erlotinib, an epidermal growth factor receptor tyrosine kinase inhibitor. *J Clin Oncol* 2004;22:3080–90.

**Source of Support:** Nil. **Conflict of Interest:** None Declared.

**Copyright:** © the author(s) and publisher. IJMRP is an official publication of Ibn Sina Academy of Medieval Medicine & Sciences, registered in 2001 under Indian Trusts Act, 1882.

This is an open access article distributed under the terms of the Creative Commons Attribution Non-commercial License, which permits unrestricted non-commercial use, distribution, and reproduction in any medium, provided the original work is properly cited.

**Cite this article as:** Pankaj Tantia, Ritika Agarwal, Jitendra Acharya. Adverse Drug Reactions of Tyrosine Kinase Inhibitors in the Treatment of Advanced Lung Cancer. *Int J Med Res Prof.* 2018 Sept; 4(5):283–85. DOI:10.21276/ijmrp.2018.4.5.064